



Michael Arnold, Christian Friedrichs, Gabriel Tulus, Stefan Verch, Holger Dennhardt, Frank Sanner

Intracoronar and intracanal endodontic diagnostics (ICD)



Michael Arnold, Dipl. Stom.
Clinician in private practice,
Dresden, Germany

Christian Friedrichs, Dr. med. dent.
Clinician in private practice,
Kiel, Germany

Gabriel Tulus, Dr. medic. stom. (RO)
Clinician in private practice,
Viersen, Germany

Stefan Verch, Dr. med. dent.
Clinician in private practice,
Berlin, Germany

Holger Dennhardt †
Clinician in private practice,
Landshut, Germany

Frank Sanner, Dr. med. Dr. med. dent.
Clinician in private practice,
Frankfurt/Main, Germany

Correspondence to:
Michael Arnold, Dipl. Stom.
Praxis für Endodontie und
Zahnerhaltung,
Königsstraße 9,
01097 Dresden, Germany.
E-mail: info@rootcanal.de

Key words dental operating microscope, diagnostics, endodontic access cavity, loupe, prognosis

Intracoronar and intracanal diagnosis (ICD) are important aspects of the endodontic diagnostic process. The intracoronar diagnosis of the pulp cavity is completed before embarking on the root canal treatment itself, while the intracanal diagnosis of the root canal systems continues throughout the instrumentation of the root canal. During this diagnostic process, the endodontist records and documents the findings using optical magnification and coaxial light. The ICD serves to verify the preliminary diagnosis and facilitates the early detection of potential complications as well as an early identification of non-salvageable teeth. Therefore, this diagnostic step is recommended both before and during root canal treatment.

■ Introduction

The endodontic diagnostic process systematically assembles general and special findings with the aim of identifying the possible causes and extent of the condition to be treated^{1,2}. After taking the medical history, it is often possible to assess the salvage ability status of an endodontically compromised tooth through a clinical examination. Based on the resultant diagnosis and an assessment of the expected treatment outcome, a first preliminary assessment can be made of the respective tooth's prognosis. In general, the use of optical magnification is recommended early in the diagnostic process to permit a better differentiation of pathological processes^{3,4}.

Informing and educating the patient about the diagnosis, treatment options, and prognosis are essential for the decision-making process in order to select an adequate treatment approach. But not all relevant aspects of endodontic treatment can be identified by conventional clinical and radiological examination methods⁵. In particular, accessory root canals systems, dentinal fracture at the bottom of

the pulp chamber, perforations, the extent and location of calcifications, or resorptive dental hard-tissue changes cannot be completely ascertained by clinical examination or two-dimensional radiology. If these internal dental findings are not included in the assessment, this can lead to misjudgements about the cause of an endodontic problem and may result in incorrect decisions regarding the indication of invasive therapy. In addition, treatment risks may be overlooked, resulting in otherwise avoidable complications adversely affecting patient health and tooth preservation⁶.

Particular importance is attached to intracoronar and intracanal diagnosis (ICD) in patients with persistent pain, which may be either odontogenic or non-odontogenic⁷. Patients with persistent pain often suffer considerably, so any treatment requires a thorough examination to confirm or exclude an endodontic diagnosis^{8,9}.

The introduction of new diagnostic tools has brought improvements in recent years. In particular, the dental microscope allows delicate structures to be recognised and treated at the same time. Thanks

to the increasingly higher resolution of dental cone-beam computed tomography (CBCT), apical pathology¹⁰⁻¹³ and anatomical variants are easier to detect¹⁴⁻¹⁸, while non-dental sources of pain have become easier to classify and diagnose¹⁹. However, alternative diagnostic approaches such as immunological²⁰ or biochemical²¹ markers are still in the early stages of being included into endodontic diagnosis.

The following article describes the procedure and the possibilities of intracoronary and intracanal diagnosis (ICD) and presents the tools required.

■ Technical prerequisites

After completing the preparation of the endodontic access cavity, it is not always possible to assess details of the pulp chamber floor and the dentine walls without optical magnification and additional lighting, even with optimal mouth opening on the part of the patient. Intracoronar diagnostics are therefore enhanced by optical magnification and a coaxial light source, which facilitate the detailed recognition of anatomical and pathological details^{1,4}.

Keplerian or Galilean loupes as well as dental microscopes are suitable for intracoronar diagnostics. Four- to eight-fold magnification is recommended during the examination²². Possible additional sources of light include halogen, metal halide, LED, or xenon lamps. An advantage when using magnifying glasses is the use of battery-powered LED lamps, since no additional wiring is required for the power supply and the weight can be kept low. For better differentiation of pathological findings obtained with the loupes, staining agents such as methylene blue (Canal blue; VDW, Munich, Germany), fuchsine or erythrosine (Caries Detector; Kuraray, Frankfurt/Main, Germany), or transillumination can be applied.

While loupes can be adequate for inspecting the pulp chamber, dental microscopes are better suited for examining the root canals. The greater the magnification, the more details can be distinguished. The use of variable magnification and its adaptation to the size of the structures to be evaluated facilitate and improve the diagnosis.

When using strong magnification of four times or higher, it is recommended to use an operator chair with tiltable arm rests (e.g. Ergo-Sit; Jadedent, Aalen, Germany) to support the lower arms. As the pulp

cavity must be viewed indirectly via dental mirrors, the use of rhodium-coated mirrors (e.g. those by Röder Dental, Ismaning, Germany) is recommended. Unlike conventional glass-veneered mirrors, these mirrors help avoid annoying double images and achieve greater light reflection with optimum colour rendering.

Important intracoronar and intracanal findings can be documented photographically – not least for forensic reasons. Certain user-friendly complete systems are being offered for this purpose, such as the Sony Nex5-based system (e.g. HanChaDent, Zwickau, Germany).

■ Intracoronar examination and diagnostic principles

Based on the anamnestic, clinical, and radiological findings, a preliminary diagnosis is made that must subsequently be checked and verified in a number of steps. An intracoronar examination should facilitate a deeper differential diagnosis and the derivation of the final diagnosis.

The prerequisite for an optimal ICD is the presence of an adequately dimensioned endodontic access cavity and the use of a magnifying tool²³. The tooth is isolated from the oral cavity with rubber dam to maintain aseptic access and to protect the patient. Prior to applying the rubber dam, the missing crown walls should be built up additively with a filling material^{1,2,24} after carefully checking the mesial and distal marginal ridges and cavity margins for cracks and fractures.

The outline of the access cavity should follow the outline, concentrically reduced, of the clinical crown (Fig 1). During preparation of the secondary access cavity under 3× to 8× magnification, the pulp chamber floor and root canal orifices are exposed so as to preserve the dentinal structures whenever possible. Pulp tissue, tertiary dentine and filling materials in retreatment cases have to be removed completely with the help of endodontic burs with long shanks (sizes 012 and 008; e.g. by Drux, Gummersbach, Germany) (Figs 2 and 3). During the tertiary preparation of the access cavity, deep preparation of the root canal orifices is performed and access to the isthmuses is prepared with a size 006 long-shafted round bur (Fig 4).

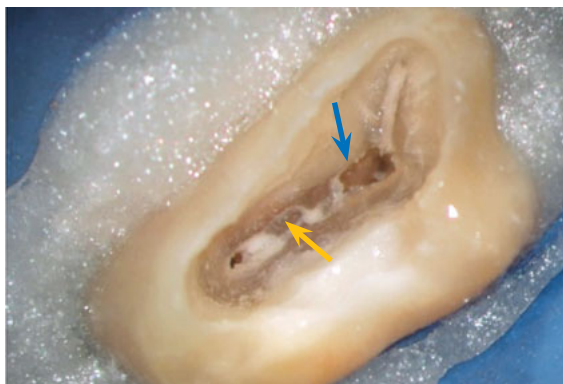

Fig 1 Following complete removal of the roof of the pulp chamber (tooth 17), the floor of the chamber becomes visible, giving a hint of the orifices of the root canals. But due to the secondary (blue arrow) and tertiary (yellow arrow) dentin encroaching on the pulp chamber, no sufficient overall assessment can be made as yet.

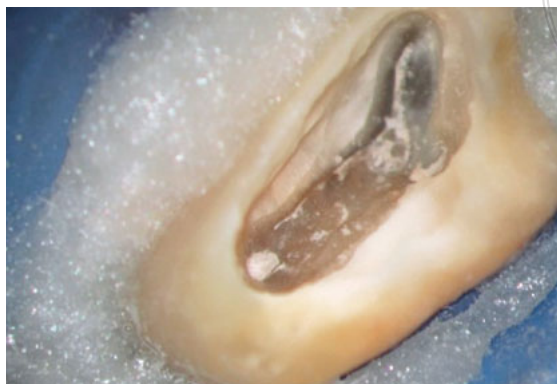

Fig 2 Reactive dentine is removed in small increments using a bur without irrigation until the orifices of the root canals are evident. The tertiary dentin appears light brown with some irregularities and extends palatally from the MB2 canal.

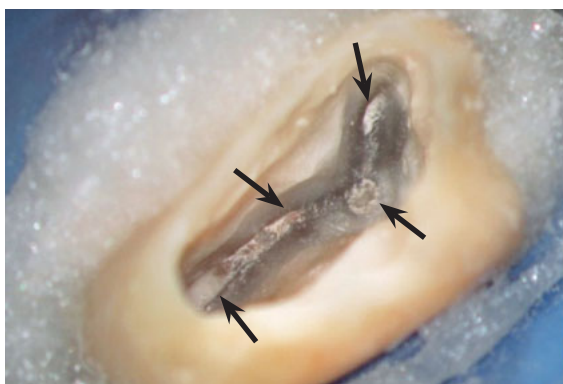


Fig 3 After the secondary access cavity is refined, all root canal orifices (arrows) are exposed.

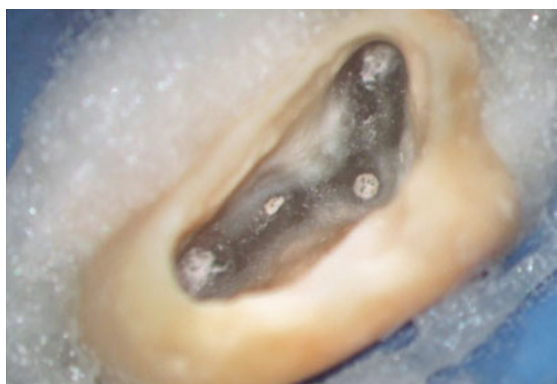

Fig 4 At this stage, the tertiary access cavity is formed by exposing potential isthmus areas and creating a small funnel to improve access to the root canal orifices.

The walls and floor of the pulp chamber are examined by visual and tactile checks. Using an ideal magnification of 4× to 16×, the structure, colour, and strength of the dentine are assessed in two steps. Due to the change in transparency, the wet and the dried surface of the dentine allow an exact evaluation of the hard tissue and the morphology of the pulp chamber walls and floor^{25,26}. Once the preparation of the tertiary access cavity is completed, the dried dentine exhibits superficially debris-filled endodontic cavities as a result of the preparation. These cavities and cracks reflect the light more strongly, appearing brighter than the surrounding dentine and thus allowing the findings to be recorded (Fig 4). The access cavity is then cleaned with an ultrasound-activated rinse with a 2% to 5% sodium hypochlorite solution. The liquid is aspirated

and the cavity reassessed in a moist medium. Due to its transparency, the still moist dentine allows the localisation of obliterated root canal structures.

All findings are documented before starting the actual root canal treatment and are therefore available for establishing a differential diagnosis (Table 1). An additional photographic documentation of the baseline situation and a recording of relevant anatomical and morphological details complete the diagnostic phase, making the findings available for later use.

■ Intracanal examination and diagnostic principles

The intracanal examination is carried out in three steps parallel to the chemical and mechanical root

Table 1 Documentation sheet for intracoronar and intracanal findings (ICD).

1	Caries	Extension
		Up to the pulp chamber
		Up to the root canal
		Up to the furcation area
2	Marginal leakage of restoration	Location
3	Dentinal cracks Crack	Extension
		Up to the cemento-enamel junction
		Up to the root canal
		Into the root canal
4	Tertiary dentine Pulp stones	Pulp chamber
		Root canal
5	Pulp tissue	Bleeding
		Purulence
		Necrotic
		Malodorous
6	Root canals	Number and location
		Treated
		Untreated
7	Isthmus areas	Location
8	Obturation material	Material
		Wall adaptation
		Strength
9	Perforation	Location
		Size
10	Resorption	Internal
		External
		Perforating
		Combined
11	Blocked canals	Partial
		Complete
12	Vertical fracture	Location
13	Separated instrument	Estimated length
		Location
		Type

canal preparation. This is an independent and distinct procedure that serves the following objectives:

1. In the case of a retreatment, identifying the causes of any persistent microbial infection.
2. Identifying risks to tooth preservation even before completing the root canal treatment.
3. Assessing the treatment of choice for its presumed effectiveness and making modifications as required.

The findings within the root canal system are recorded under optical control with a dental microscope at 8× to 30× magnification.

After completing each enlargement step of the coronal, middle, and apical thirds of the root canal, the root canals are irrigated with ultrasonically activated 2% to 5% sodium hypochlorite solution and thereafter dried. While the situation in the coronal and middle third of the root canal system can be assessed visually under the microscope, the corresponding assessment in the apical third — except with very straight root canal systems — frequently has to be made indirectly.

A size 10 MicroOpener (Maillefer, Ballaigues, Switzerland), pre-bent at the instrument tip, enables visually controlled probing of the root canal walls. Organic debris laterally attached to the canal wall is often a first indication of larger lumens of the root canal system, which can be accessed using with minimal invasive procedures²⁷. The apical canal third can be examined by “apical gauging,” by taking an “impression” with thermally softened gutta percha²⁸ and using the paper point test²⁹.

■ Possible diagnostic findings

The visual and tactile examination of the dentine is at the core of the first diagnostic phase. A decisive factor for assessing the viability of a tooth is to determine of the extent to which the hard tissue has been damaged by caries. Especially if a carious lesion extends below the gingival margin or is located in close proximity to filling material, it will be difficult to assess the problem merely by a clinical or radiological examination (Fig 5).

Due to the caries-related colour changes of the dentine, it is possible to accurately detect the presence and extent of decay during the intracoronar examination (Fig 6). Crowns and bridge restorations can be checked for tightness of seal (or, conversely, coronal leakage)²⁵. The diagnosis of pulp stones and calcifications are additional aspects of the intracoronar examination.

For the next step of the ICD, the baseline status of the root canal system and the pulp tissue are macroscopically analysed and documented. A clear distinction is possible between blood-supplied tissue, partially blood supplied tissue, and necrotic pulp

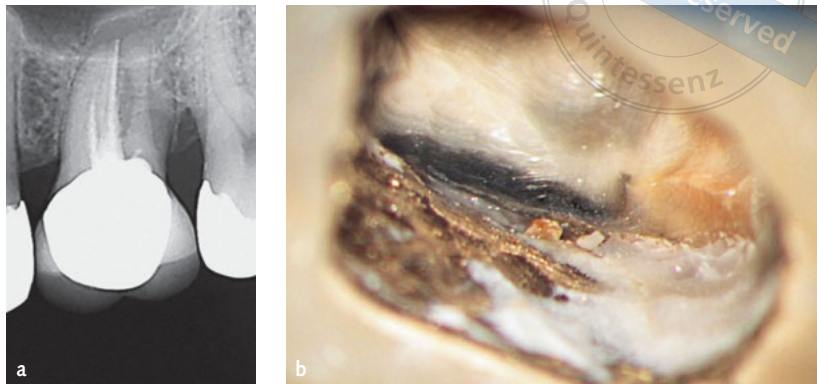


Fig 5 While no marginal gap or caries can be detected on the radiograph (a) of tooth 26, the ICD shows a marginal gap and brownish discoloured carious dentine (b) at the mesial crown margin.

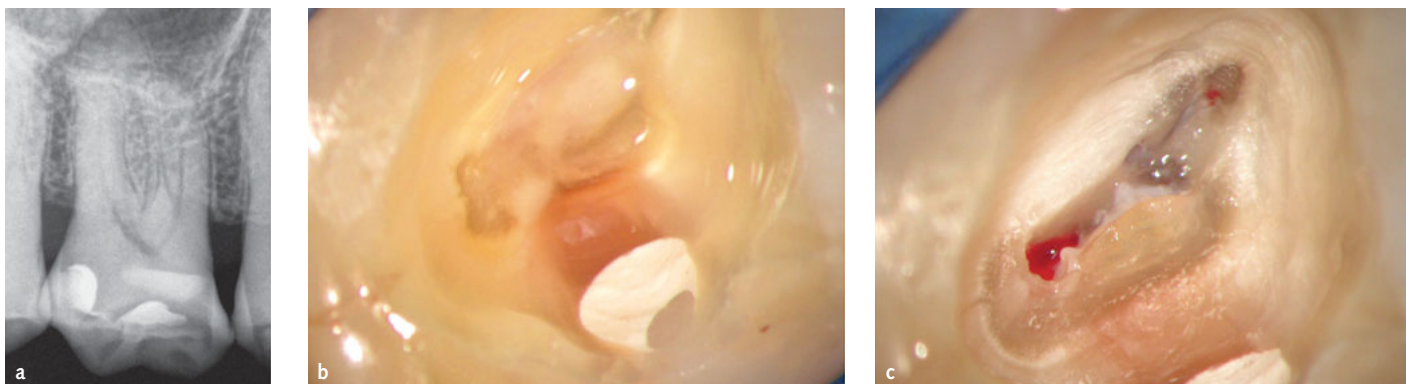


Fig 6 The patient complained about radiating, recurrent pain that could be elicited by heat. Both trigeminal neuralgia and irreversible pulpitis were included in the differential diagnosis. a) The radiograph showed no pathology; b) The ICD showed brownish discoloured dentine extending to the pulp chamber, which was encroached on by tertiary dentine; c) In the palatal root, partly necrotic and profusely bleeding pulp tissue was found. The preliminary diagnosis of irreversible pulpitis was confirmed.

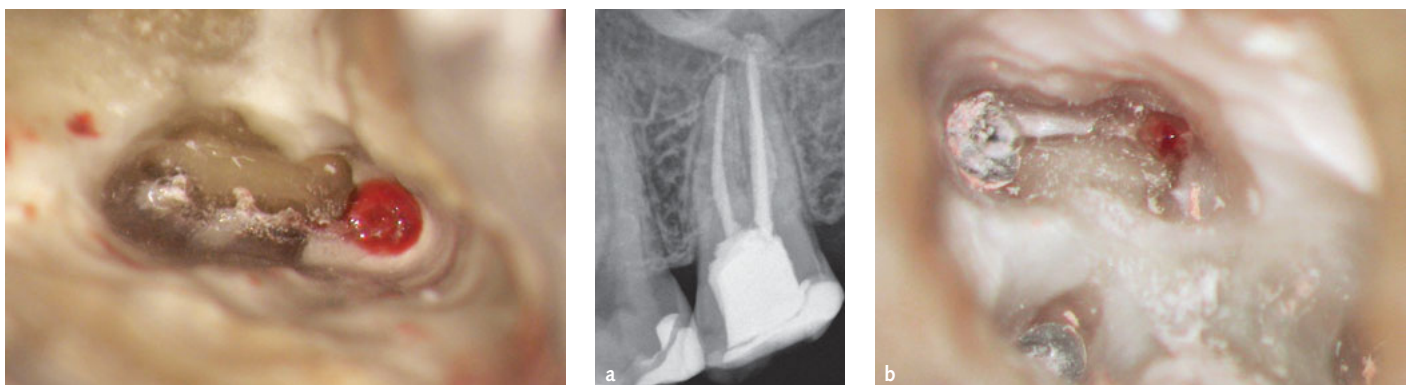


Fig 7 Enlarged view of the three mesiobuccal root canal orifices of tooth 26. Only one root canal (MB1) still contains bleeding pulp tissue.

Fig 8 The patient complained about persistent lingering pain on exposure to heat after the root canal treatment had been completed. a) On the radiograph, the root canal filling seemed to be complete, so the patient was referred for apical surgery; b) The ICD was able to demonstrate a second mesiobuccal root canal with bleeding and sensitive pulp tissue. The preliminary diagnosis of chronic apical periodontitis was not confirmed and a diagnosis of irreversible pulpitis was made instead.

tissue (Figs 7 and 8). In particular, the presence and localisation of tertiary dentine and pulp stones indicate that the pulp may be engaged in defensive processes (Fig 6) and allow conclusions about its pathogenesis³⁰.

The number of root canal orifices as well as the presence and extent of isthmus structures can be determined under magnification (ideally 4x to 16x). Very wide or even ampoule-shaped root canal openings require a differentiated preparation

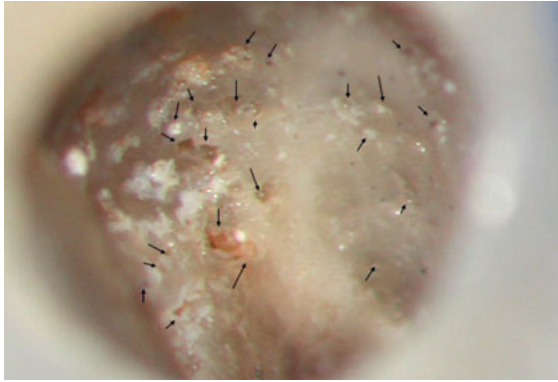


Fig 9 Multiple resorption pits on the surface of a root canal. In some of the pits, residue of calcium hydroxide was visible. The caries-free tooth 23 was affected by an invasive cervical resorption that had ultimately been causing the pulpitis.

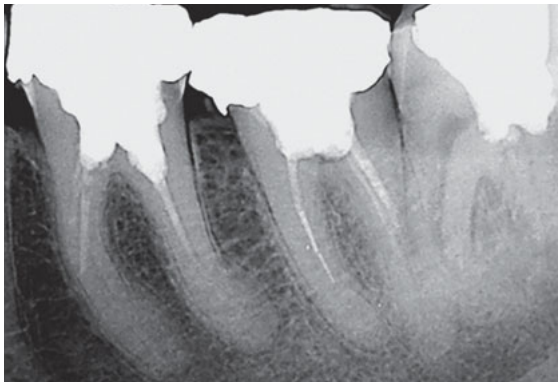


Fig 10a Incomplete root canal fillings on teeth 36 and 37 on the diagnostic radiograph.

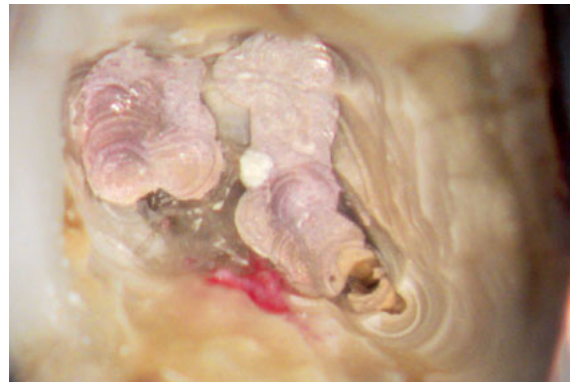

Fig 10b During the ICD in both teeth, vital and bleeding tissue is visible on the lingual side of the pulp chamber floor, which in tooth 37 turned out to derive from a previously untreated additional root canal with vital pulp tissue.

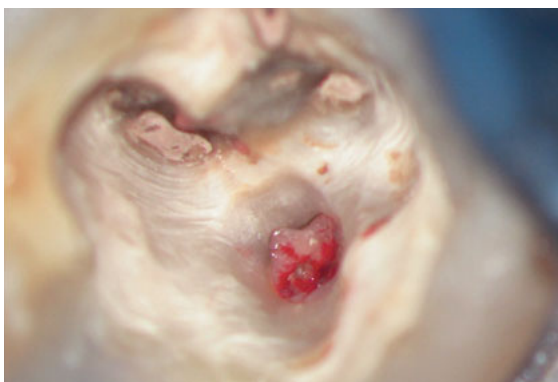

Fig 10c Tooth 36 exhibited a perforation. In addition, two more root canals were found buccally. The differential diagnosis was made by means of an apex locator. The instant apex display facilitated the timely recognition of the perforation.

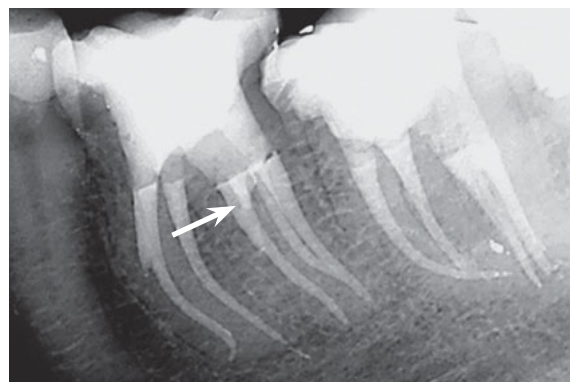


Fig 10d Actual positions of the root canals and the perforation (arrow) can only be guessed on the control radiograph taken after completion of the root canal treatment, even in the distal eccentric projection.

concept that is tailored to the actual morphology. In the case of a retreatment, untreated root canals can thus be distinguished from treated and obturated ones. Under magnification and the possible additional use of staining agents, the wall adaptation of the root canal filling material in the coronal third of

the root can be more easily ascertained. The type and consistency of the filling material are evaluated. Depending on the nature of the root canal filling material, an effective method and strategy for possible removal can be selected as early as during the ICD.

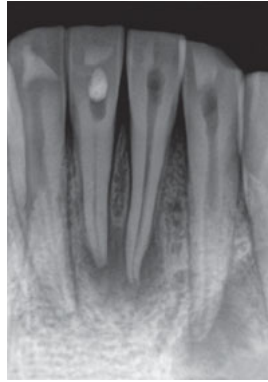

Fig 11a Tooth 41 had suffered a trauma that led to partial obliteration and subsequent pulp infection and necrosis. The radiograph showed a greatly narrowed root canal system up to the middle third.

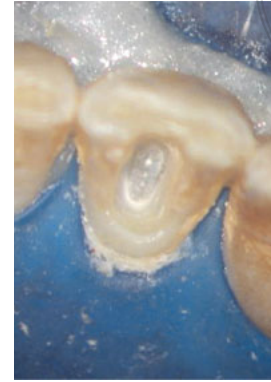

Fig 11b During the ICD, the tertiary dentine was clearly visible. Centrally located lumens could not yet be negotiated with hand instruments at that point.

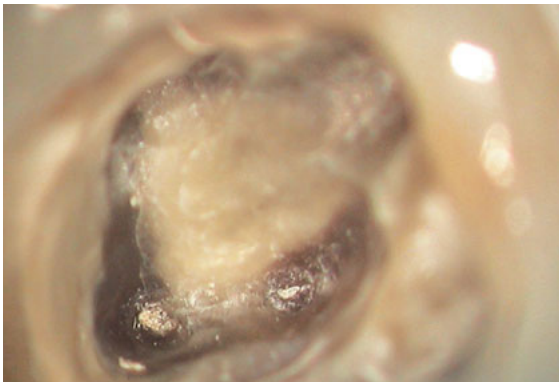


Fig 12 A dentinal stress crack is visible at the level of the cemento-enamel junction of tooth 16.

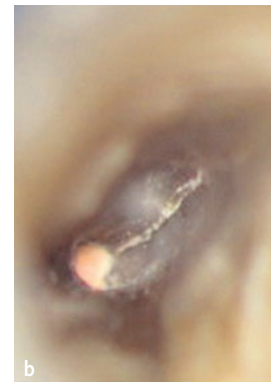
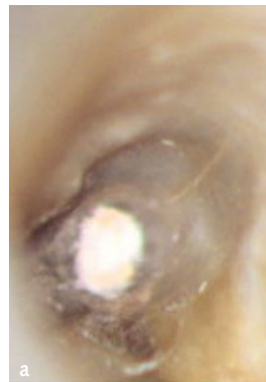
Fig 13 No pathological probing depths were found at tooth 16. a) During the ICD, a fine mesiobuccal crack was seen in the dentine, beginning at the root canal orifice; b) After further root canal preparation, the width of the crack increased, and an early vertical fracture was diagnosed.

During the inspection, root canal openings can be differentiated from resorptive perforations (Fig 9) or artificial channels and perforations. It is recommended to test this using electrometry (Fig 10), which determines the position and extent of the perforation in order to be able to select an adequate obturation material. At the same time, the perforation can be checked for displaced or over-instrumented obturation material, so that a decision in favour of an orthograde, retrograde or combined treatment plan can be made.

Obliterated root canal systems pose challenges for diagnosis and therapy alike³¹. The further the root canal system narrows as a result of irritation or age, the more difficult it is to find it and to enlarge it mechanically. Indications of the former locations of root canals can be found in minuscule debris deposits or differences in the dentine colour (Fig 11).

Fractures and cracks are best identified after dry preparation with round burs. The preparation on

the dentine leads to the smoothing and removal of adhering soft and hard tissue residues but also marks even the minutest cavities by pressing debris into them. In terms of colour, they are characterised by greater reflectivity and therefore present as brighter lines. Mesiodistal dentine fractures (cracks) are often a consequence of dehydration or mechanical overload³². Their expansion is from coronal to apical (Fig 12). Vertical fractures usually originate in the apical or middle third of the root and extend vertically in an apical and coronal direction (Fig 13)³³. The ICD allows the differential diagnosis and early detection of vertical fractures even before clinical symptoms appear or a discernible vertical collapse of the periodontium has occurred so that affected teeth can be removed in a timely manner. The additional use of an electronic apex locator is a good way to confirm or reject visually determined preliminary diagnoses of intracanal perforations and cracks.

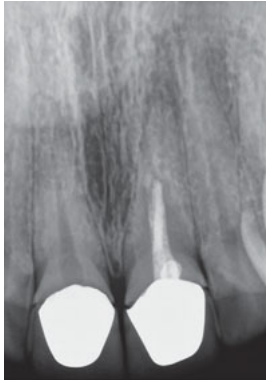

Fig 14a The diagnostic radiograph raised the suspicion of a ledge and incomplete root canal filling in the presence of an apical radiolucency.

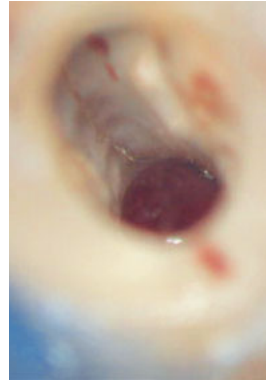


Fig 14b During the ICD, after removal of the root canal filling, a crack and an extensive perforation were seen when looking at the vestibular root canal wall. The preliminary diagnosis was not confirmed.

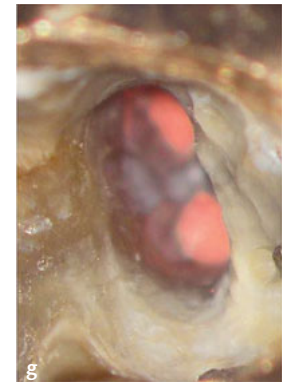
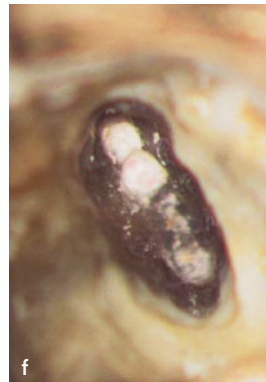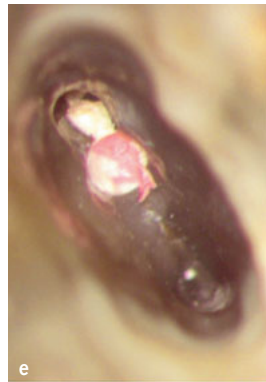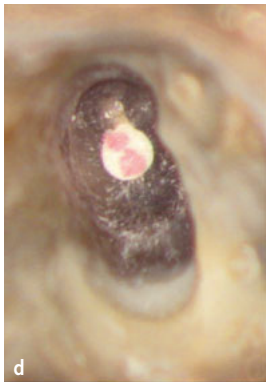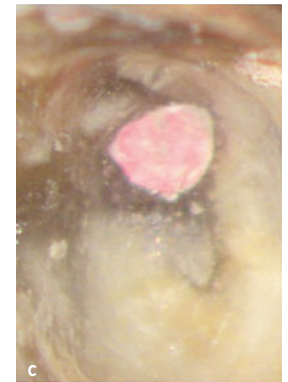


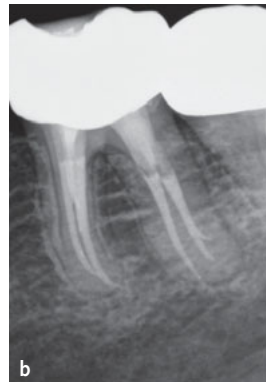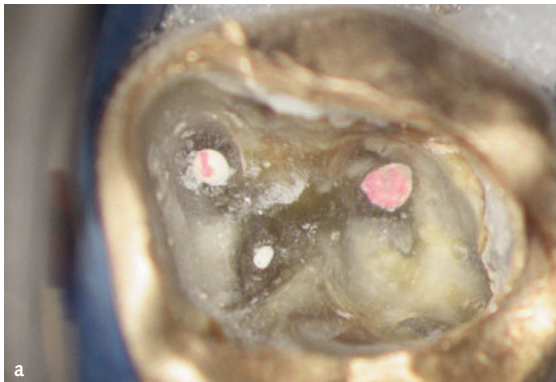Fig 15 During the ICD, three obturated root canals were initially exposed. Not until deeper areas of the distal root canal system were exposed two separate canals in the distal root become evident.

■ Intracanal findings and diagnostics

During intracanal diagnosis, as root canal enlargement progresses, root canals are examined for cracks (Fig 13b), isthmus areas, ledges, obliterations, perforations (Fig 14), instrument fragments, adherent tissue or filling remnants, deep divisions, or confluences (Fig 15). In confluent root canal systems one must watch out for bifurcations beyond the

confluency²⁷. Seemingly false-positive electrometric measurement results can be visually double-checked under the microscope for the presence of lateral pulpo-desmodontal root canals, so that errors in determining working lengths can be reduced. Timely recognition of large apical foramina by probing or, if possible, visual inspection facilitates the selection of a suitable obturation material.

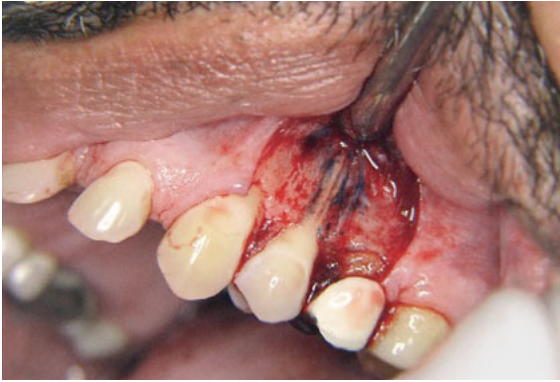

Fig 16 Vertical root fracture with loss of the bone lamella in the entire fracture area. For better visibility of the fracture line, methylene blue staining had been performed.

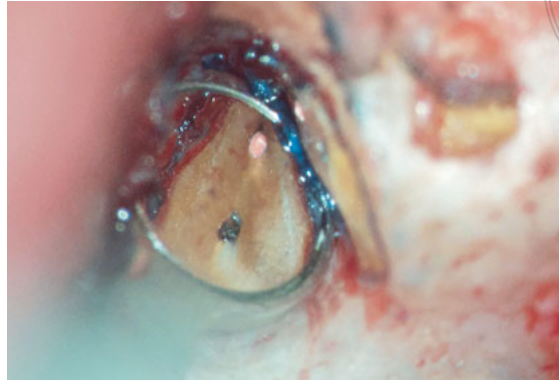

Fig 17 ICD of the resected surface of a mesiobuccal root of tooth 16. Methylene blue staining exposed the incomplete obturation of both root canals. No fracture was present.

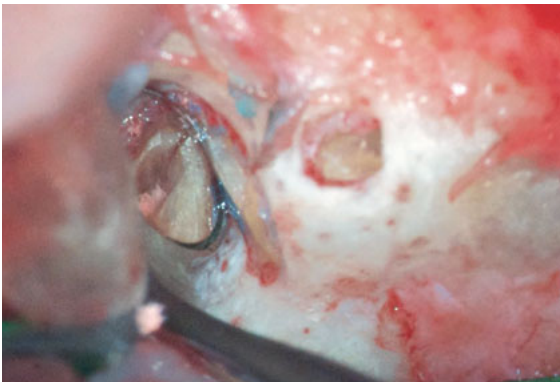

Fig 18 During the ICD, a crack on the resected root surface appeared on the mesiobuccal root tip of tooth 16. Only the retrograde preparation revealed the extent of the crack, as far as the middle third of the root.

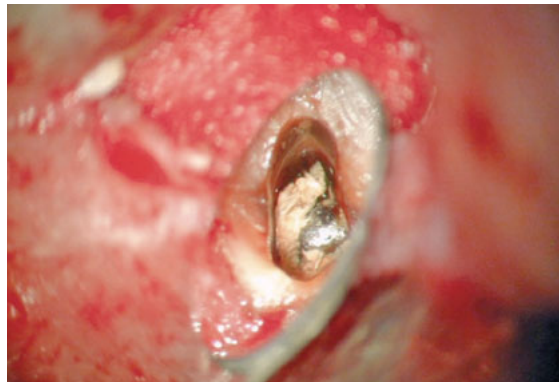

Fig 19 Following the resection and retrograde preparation of tooth 11 supplied with a metal post, the root surface and the root canal were examined for fractures. The adhesive luting material not directly attached to the wall was to be ultrasonically reduced in a minimally invasive procedure prior to retrograde filling.

■ Special requirements for retrograde endodontics

An essential prerequisite for using ICD in the course of root-end surgery is the proper preparation of the surgical field. Optimal hemostasis through the use of hemostatic agents³⁴, the flap design, and an adequately dimensioned bony access facilitate a first macroscopic evaluation of the surgical site to exclude vertical fractures even before initiating resective therapy (Fig 16)^{34–37}. Following enucleation of the apical lesion, the additional use of hemostatic agents is recommended³⁴. At about 3× to 10× magnification, apical perforations, fractures and resorbed root canals can be differentiated at the apex^{36,37}.

Following minimally invasive apical resection perpendicular to the root axis and subsequent drying, a first examination is made of the resection slide, looking for the presence of a root canal filling, its wall adaptation, the presence of further endodontic cavities, isthmus areas³⁸, cracks³⁹, and resorptive lesions (Figs 17 and 18). In addition, the type the filling material used in the primary treatment can be determined, so that a suitable method for retrograde removal can be chosen (Fig 19). If metal posts or fragments are detected, their exact location and type and size is determined in order to achieve complete and residue-free removal. Staining of the resection slide with methylene blue and evaluation under indirect vision using a micro-mirror are recommended^{35–37,40}. On completion of

the retrograde revision and the preparation of the retrograde cavity, the final intracanal examination is performed, confirming or rejecting the preoperative preliminary diagnosis intraoperatively on the basis of the ICD.

■ Discussion


The external dental findings collected in the course of endodontic diagnostics constitute essential initial information that, compounded by anamnestic data and radiological findings, justifies a presumptive diagnosis¹. The pain history, being non-objective, is not strictly correlated to a specific pathological process¹ but still provides important anecdotal information that may assist in arriving at a preliminary diagnosis. Any evaluation of two-dimensional radiographs is to a considerable extent subject to interpretation, due to the unavoidable superimposition of three-dimensional structures on a two-dimensional plane. Inter- and intra-individual differences in the assessment of two-dimensional radiographs further reduce their diagnostic accuracy^{13,41-43}. Thus, regardless of the selected radiographic technique, the number of root canals and the shape of the root canal system can only be estimated. The quality of a previous root canal treatment can only be roughly assessed, as no

information can be derived on the actual length of the root canal in relation to the root length due to the lack of a third dimension in the reconstruction. The CBCT technique allows for a more extensive radiological diagnosis, but is not generally indicated before each endodontic procedure because of the increased radiation exposure⁴⁴. Even if CBCT is available, it is not possible to reliably exclude a vertical fracture⁴⁵, so that invasive examinations in terms of an ICD are recommended for a differential diagnosis. CBCT images allow for an exact determination of the external contours of the root and periradicular pathological processes. Even parts of a root canal inadvertently left untreated can sometimes be identified. The recordings, however, do not facilitate the reliable recognition of partially obliterated root canals and isthmus areas¹⁸. These can only be determined by intracoronar and intracanal diagnostics under optical magnification (Table 2). The combination of dental microscopy and CBCT enhances the safety of minimally invasive root canal detection even in deeper regions of the root canal system, further reducing the need for retrograde surgical intervention^{18,45}.

In any event, an ICD is recommended before embarking on root canal preparation^{1,6,23,25,26,46,47}. The use of optical magnification and sufficient lighting are recommended, as a shadow-free illumination of the endodontic access cavity facilitates correct

Table 2 Comparison of modern diagnostic approaches. Microscopic evaluation can be performed continuously and concurrently with root canal treatment.

	No visual magnification	Radiological, including CBCT	ICT – diagnosis with loupes or dental microscopes
Pulp chamber floor	Difficult	Number and dimensions of roots, relation to adjacent anatomical structures	Visualisation of pulp stones, debris, blocked canal structures, fractures, perforations, resorptions
Coronal and middle thirds of the root	Difficult, limited to coronal third, not possible beyond the middle of the canal	Detection of root canals restricted by the resolution of the device used	Residual pulp tissue, root canal, accessory canals, isthmus areas, fins, deep bifurcations, broken instruments, perforations, resorption
Apical third of the root	Not possible	Extend and location of pathological processes (resorption, periapical bone lesions) and traumatic changes	In teeth with an open apex or after apical resections or in straight canals up to the periapical tissue
Endodontic surgery	Difficult	Relation to adjacent anatomical structures	Accessory canal structures, isthmus areas, fractures, cleanliness of retrocavity, quality of retrofill



findings^{1,4}. The higher and more variable the magnification available, the greater the sensitivity of the examination procedure⁴, and the greater the chance of improving the results⁴⁸⁻⁵⁵. The diagnostic specificity of the ICD procedure depends upon operator experience and a thorough knowledge of the anatomy and morphology of dental structures³. Daily use of the dental microscope or loupes increases the information benefit and trains the acuity of operators in recognising dental structures³.

Reliable detection of caries that extends into the pulp cavity allows its timely and complete removal to prevent microbial reinfection during endodontic therapy. During an ICD, the root canal structures branching off from the pulp chamber can be detected with great certainty, with the use of the microscope leading to a higher rate of discovered root canal orifices, as has been proven for MB2 on multiple occasions^{55,56}. Vertical fractures can be detected early and safely up to the middle third of the root using the ICD, so the patient can be spared unpromising therapeutic attempts. Other diagnostic procedures, such as circular probing and radiography, do not offer the same level of diagnostic certainty but are still required for primary diagnosis. Not until the fracture gap has been colonised by microorganisms can the typical vertical collapse so typical of vertical fractures be measured with a (maximally flexible) periodontal probe. Its radiological detection depends on an already existing gap in the root dentine or the presence of a laterally limited radiolucency^{57,58}. Perforations can be safely differentiated from root canals using ICD as well as apex locators, so that risks to patients caused by improper instrumentation and irrigation can be avoided.

During the ICD, open questions on the pathogenesis can often be narrowed down more clearly by systematic assessment. As part of a structured endodontic diagnostic process, ICD is an important way to obtain objective information about the intracoronar factors involved and helps assess more reliably the difficulty of the procedure and the long-time prognosis of the tooth in question.

References

1. Klimm W. Endodontologie. Grundlagen und Praxis. Köln: Deutscher Zahnärzte Verlag, 2003.
2. Hülsmann M. Checklisten der Zahnmedizin. Endodontie. Stuttgart: Georg Thieme Verlag, 2008.
3. Koch K. The microscope. Its effect on your practice. Dent Clin North Am 1997;41:619-626.
4. Zaugg B, Stassinakis A, Hotz P. [Influence of magnification tools on the recognition of simulated preparation and filling errors]. Schweiz Monatsschr Zahnmed 2004;114:890-896.
5. West JD. Endodontic diagnosis. Mystery or mastery? Dent Today 2004;23:80-87.
6. Selden HS. The role of the dental operating microscope in endodontics. Pa Dent J (Harrisb) 1986;53:36-37.
7. Nixdorf DR, Moana-Filho EJ, Law AS, McGuire LA, Hodges JS, John MT. Frequency of nonodontogenic pain after endodontic therapy: a systematic review and meta-analysis. J Endod 2010;36:1494-1498.
8. Sanner F. Zahnschmerzen nichtdentogener Genese – Diagnostische Aspekte. Endodontie 2008;17:217-226.
9. Sanner F. Acute right-sided facial pain: a case report. Int Endod J 2010;43:154-162.
10. Patel S, Dawood A, Ford TP, Whaites E. The potential applications of cone beam computed tomography in the management of endodontic problems. Int Endod J 2007;40:818-830.
11. Bornstein MM, Lauber R, Sendi P, von Arx T. Comparison of periapical radiography and limited cone-beam computed tomography in mandibular molars for analysis of anatomical landmarks before apical surgery. J Endod 2011;37:151-157.
12. Abella F, Patel S, Duran-Sindreu F, Mercadé M, Bueno R, Roig M. Evaluating the periapical status of teeth with irreversible pulpitis by using cone-beam computed tomography scanning and periapical radiographs. J Endod 2012;38:1588-1591.
13. de Paula-Silva FW, Wu MK, Leonardo MR, da Silva LA, Wesselink PR. Accuracy of periapical radiography and cone-beam computed tomography scans in diagnosing apical periodontitis using histopathological findings as a gold standard. J Endod 2009;35:1009-1012.
14. Matherne RP, Angelopoulos C, Kulild JC, Tira D. Use of cone-beam computed tomography to identify root canal systems in vitro. J Endod 2008;34:87-89.
15. Michetti J, Maret D, Mallet J.-P, Diemer F. Validation of cone beam computed tomography as a tool to explore root canal anatomy. J Endod 2010;36:1187-1190.
16. Patel S. The use of cone beam computed tomography in the conservative management of dens invaginatus: a case report. Int Endod J 2010;43:707-713.
17. Abella F, Mercadé M, Duran-Sindreu F, Roig M. Managing severe curvature of radix entomolaris: three-dimensional analysis with cone beam computed tomography. Int Endod J 2011;44:876-885.
18. Arnold M. Anwendung der dentalen digitalen Volumetomographie in der Endodontie. Quintessenz 2013;64:85-96.
19. Classification of chronic pain. IASP 2012 2nd edition. http://www.iasp-pain.org/AM/Template.cfm?Section=Classification_of_Chronic_Pain&Template=/CM/Content-Display.cfm&ContentID=16276.
20. Marending M, Peters OA, Zehnder M. Factors affecting the outcome of orthograde root canal therapy in a general dentistry hospital practice. Oral Surg Oral Med Oral Pathol Oral Radiol Endod 2005;99:119-124.
21. Zehnder M, Wegehaupt FJ, Attin T. A first study on the usefulness of Matrix Metalloproteinase 9 from dentinal fluid to indicate pulp inflammation. J Endod 2011;37:17-20.
22. Arnold M. Visualisierung. In: Hülsmann M, Schäfer E. Probleme in der Endodontie. Berlin: Quintessenz Verlag, 2007.

23. Betz W. Unterstützende Sehhilfen in der Zahn-, Mund und Kieferheilkunde. Stellungnahme der DGZMK V 1.0. DZZ 53 (98).
24. Arnold M. Präendodontischer Aufbau und problemorientierte Gestaltung der endodontischen Zugangskavität. *Quintessenz* 2012;63:439–448.
25. Mounce RE. Surgical operating microscopes in endodontics: the paradigm shift. *Gen Dent* 1995;43:346–349.
26. Friedrichs C. Die endodontische Landkarte. Orientierungshilfen zur Präparation der Zugangskavität und der Darstellung der Kanalsysteme – Teil 1. *Endodontie* 2010;19: 355–363.
27. Arnold M, Paqué F. Klinisches Management x-förmiger Wurzelkanalkonfigurationen bei ersten Oberkiefermolaren. *Endodontie* 2010;19:399–409.
28. Kerezoudis NP, Valavanis D, Prountzos F. A method of adapting guttapercha master cones for obturation of open apex cases using heat. *Int Endod J* 1999;32:53–60.
29. Marcos-Arenal JL, Rivera EM, Caplan DJ, Trope M. Evaluating the paper point technique for locating the apical foramen after canal preparation. *Oral Surg Oral Med Oral Pathol Oral Radiol Endod* 2009;108:e101–105.
30. Koçkapan, C. Die Struktur des Wurzelkambiums. *Endodontie* 2012;21:113–128.
31. McCabe PS, Dummer PM. Pulp canal obliteration: an endodontic diagnosis and treatment challenge. *Int Endod J* 2012; 45:177–197.
32. Bajaj D, Sundaram N, Nazari A, Arola D. Age, dehydration and fatigue crack growth in dentin. *Biomaterials* 2006; 27:2507–2517.
33. Rivera EM, Walton RE. Longitudinal root fractures: findings that contribute to complex endodontic diagnosis. *Endodontic Topics* 2009;16:82–111.
34. Kim S, Rethnam S. Hemostasis in endodontic microsurgery. *Dent Clin North Am* 1997;41:499–511.
35. Kim S. Principles of endodontic microsurgery. *Dent Clin North Am* 1997;41:481–497.
36. Velvart P. [The operating microscope in root tip resection. II. Retrograde care]. *Schweiz Monatsschr Zahnmed* 1997;107:968–983.
37. Velvart P. [The operating microscope in root tip resection. I. The resection]. *Schweiz Monatsschr Zahnmed* 1997;107: 506–521.
38. Hsu YY, Kim S. The issue of canal isthmuses. *Dent Clin North Am* 1997;41:529–540.
39. Slaton CC, Loushine RJ, Weller RN, Parker MH, Kimbrough WF, Pashley DH. Identification of resected root-end dentinal cracks: A comparative study of visual magnification. *J Endod* 2003;29:519–522.
40. Rubinstein RA, Kim S. Long-term follow-up of cases considered healed one year after apical microsurgery. *J Endod* 2002;28:378–383.
41. Goldman M, Pearson AH, Darzenta N. Endodontic success-who's reading the radiograph? *Oral Surg Oral Med Oral Pathol* 1972;33:432–437.
42. Goldman M, Pearson AH, Darzenta N. Reliability of radiographic interpretations. *Oral Surg Oral Med Oral Pathol* 1974;38:287–293.
43. D'Addazio PS, Campos CN, Özcan M, Teixeira HG, Passoni RM, Carvalho AC. A comparative study between cone-beam computed tomography and periapical radiographs in the diagnosis of simulated endodontic complications. *Int Endod J* 2011;44:218–224.
44. American Association of Endodontists; American Academy of Oral and Maxillofacial Radiography. AAE and AAOMR joint position statement. Use of cone-beam-computed tomography in endodontics. *Pa Dent J (Harrisb)* 2011;78:37–39.
45. Bürklein S. DVT in der Endodontie. *Endodontie* 2011;20: 381–388.
46. European Society of Endodontology. Quality guidelines for endodontic treatment: consensus report of the European Society of Endodontology. *Int Endod J* 2006;39:921–930.
47. AAE Position Statement. Use of microscopes and other magnification techniques. *J Endod* 2012;38:1153–1155.
48. Baldassari-Cruz LA, Lilly JP, Rivera EM. The influence of dental operating microscope in locating the mesiolingual canal orifice. *Oral Surg Oral Med Oral Pathol Oral Radiol Endod* 2002;93:190–194.
49. Wolcott J, Ishley D, Kennedy W, Johnson S, Minnich S, Meyers J. A 5 yr clinical investigation of second mesiobuccal canals in endodontically treated and retreated maxillary molars. *J Endod* 2005;31:262–26.
50. Tsesis I, Rosen E, Schwartz-Arad D, Fuss Z. Retrospective evaluation of surgical endodontic treatment: traditional versus modern technique. *J Endod* 2006;32:412–426.
51. Tsesis I, Faivishvsky V, Kfir A, Rosen E. Outcome of surgical endodontic treatment performed by a modern technique: a meta-analysis of literature. *J Endod* 2009;35: 1505–1511.
52. Setzer FC, Shah SB, Kohli MR, Karabucak B, Kim S. Outcome of endodontic surgery: a meta-analysis of the literature--part 1: Comparison of traditional root-end surgery and endodontic microsurgery. *J Endod* 2010;36:1757–1765.
53. Setzer F, Kohli M, Shah S, Karabucak B, Kim S. Outcome of endodontic surgery: A Meta-analysis of the literature - Part 2: Comparison of endodontic microsurgical techniques with and without the use of higher magnification. *J Endod* 2012;38:1–10.
54. Levenson D. Higher powered magnification improved endodontic surgery outcomes. *Evid Based Dent* 2012;13: 109.
55. Carr GB, Murgel C A. The use of the operating microscope in endodontics. *Dent Clin North Am* 2010;54:191–214.
56. Schwarze T, Baethge C, Stecher T, Geurtsen W. Identification of second canals in the mesiobuccal root of maxillary first and second molars using magnifying loupes or an operating microscope. *Aust Endod J* 2002;28:57–60.
57. Hassan B, Metska ME, Ozok AR, van der Stelt P, Wesselink PR. Detection of vertical root fractures in endodontically treated teeth by a cone beam computed tomography scan. *J Endod* 2009;35:719–722.
58. Mora MA, Mol A, Tyndall DA, Rivera E. In vitro assessment of local tomography for the detection of longitudinal tooth fractures. *Oral Surg Oral Med Oral Pathol Oral Radiol Endod* 2007;103:825–829.